

ORIGINAL ARTICLE

# Anterior Single Lag Screw Fixation in Type II Odontoid Process Fractures

Mohsen Dalvandi<sup>1</sup>, Ali Reza Mohamadi<sup>2</sup>, Sayed Ali Ahmadi<sup>3</sup>

<sup>1</sup> Department of Neurosurgery, Arak University of Medical Sciences, Arak, Iran; <sup>2</sup> Department of Neurosurgery, Arak University of Medical Sciences, Arak, Iran; <sup>3</sup> Department of Neurosurgery, Arak University of Medical Sciences, Arak, Iran

**Key words:** Odontoid Process, Fracture Fixation, Anterior Cervical Fusion, Screw Fixation

**ABSTRACT**

**Introduction:** Anterior screw fixation provides the best anatomical and functional results for type II odontoid process fracture with intact transverse ligament. The purpose of this study was to report the usefulness of single lag screw and relate our experience.

**Methods:** From 2008 to 2013, 37 cases of acute type II dens fracture were treated with anterior single screw fixation in our center. All patients underwent standard approach identical to the C2-C3 and using fluoroscopic guidance; a Kirschner wire (K wire) was inserted at the anterior lip of C2 in a sagittal direction angled posteriorly and exited the posterior tip of odontoid. The trajectory was confirmed with two plan imaging then the final lag screw was inserted in through the guide tube.

**Results:** There were 26 male and 11 female patients

with type II odontoid process fracture whose ages ranged from 8 to 67 yr (mean 27.27 yr). In all cases, the screw could be successfully introduced crossing the fracture site and engaging the dens. On follow up of all cases, 100% good fusion was achieved. No case of non-union was observed. There were no major neurological complications. None of the patients developed operative site infection, CSF fistula, esophageal tear, submandibular fistula or hypoglossal nerve paresis. There was no screw breakage in follow-up. Transient dysphagia was present in 18 cases, which improved.

**Conclusion:** Anterior single lag screw fixation is a very useful method in anterior fixation for type II odontoid process fracture. This case series showed successful results also in type II odontoid fracture when treated with the single lag screw. *JOURNAL OF IRANIAN CLINICAL RESEARCH* 2015;1(2):62-66

**INTRODUCTION**

Approximately 10% to 15% of all cervical fractures are odontoid fractures, with most (65% to 74%) being type II fractures. C2 fractures are classified as odontoid fractures involving the dens. Hangman's fractures and miscellaneous fractures, including facet fractures or injury through the foramen transversarium [1].

Anderson and D'Alonzo classified odontoid fractures into three types according to the fracture position [2]. Type I fractures are relatively rare; the fracture line traverses the odontoid tip superior to the transverse ligament. Type II fractures are the most common and the fracture line traverses the odontoid base. Type IIa fractures is a subtype

where there is communicated fracture of the odontoid process base. Type III fractures include the body of C2 [2]. Type I and III injuries are considered stable and do not require surgical treatment but the ideal treatment for type II injuries is controversial [2].

Currently, in addition to nonsurgical treatments including semirigid collars or the Halo-thoracic-vests (HTV), there are many surgical techniques for the treatment of C2-fractures including anterior odontoid screw fixation (AOSF) [3-4], posterior stabilization techniques, such as the methods described by Brooks and Jenkins [5], Gallie [6], and Sonntag et al. [7] and posterior transarticular screw fixation of C1-2 [8]. Posterior stabilization techniques have several disadvantages, including relatively high rates of perioperative morbidity (ranging from 5% to 19%) [4-5, 9-10]. Perhaps the greatest

Correspondence: Ali Ahmadi, Associate Professor of Neurosurgery, Department of Neurosurgery, Arak University of Medical Sciences and Health Services, Arak, Iran. Email: Ahmadi.sayedali@gmail.com.

disadvantage of fusion is the loss of axial rotation after fusion [11].

Direct anterior screw fixation provides immediate spinal stabilization, preserves rotation of C1 on C2, and allows rapid return to normal lifestyle [12-13]. Retention of full range of motion has been 83% [14].

We designed this preliminary study to reviews our clinical experience of single odontoid screw fixation for the treatment of Type II odontoid fractures.

## MATERIALS AND METHODS

From January 2008 to December 2013, 37 cases of acute type II dens fracture with 6 mm or more displacement of odontoid was treated in our center. Our case exclusion criteria were type II dens fracture of more than 2 months duration, type I and III fractures and other types of C2 fractures, significant comminution of the C2 body and all cases with rupture of the transverse ligament (assessed with MRI). In all patients x-ray, computed tomography (CT) scan and magnetic resonance imaging (MRI) of cervical spine were done.

### Surgical Technique

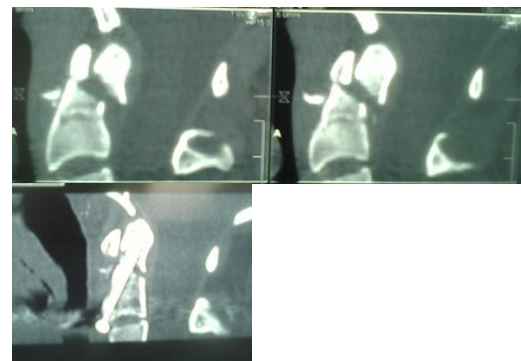
All patients underwent nasotracheal or fiberoptic endotracheal intubation while conscious. After induction of general anesthesia, the patients were placed in the supine position. A transverse shoulder roll was placed to create slight cervical hyperextension. Portable anterior (AP) and lateral fluoroscopy equipment was used for imaging of the cervical spine, to verify the proposed trajectory and adequacy of fracture reduction. A radiolucent bite-block (gauze roll) was placed in the mouth to permit an unobstructed anteroposterior view of the odontoid process. A standard transverse skin incision was made over the C5-6 disk space. The platysma muscle was opened, and blunt dissection was used to access the corridor to the ventral spine. We approached the cervical spine from the left side to avoid injury to the recurrent laryngeal nerve, which had a more variable course on the right. Once the ventral spine was palpated, handheld retractors were used, and the longus colli was incised (often with cautery) and swept laterally off the midline. The soft tissue was opened cephalad to the C2 region to allow access to the C2-3 disk space. At this point in the procedure, cannulation of the fracture was begun. The C2-3 anulus was opened as the starting point for drilling, and a Kirschner wire (K wire) was inserted at the anterior lip of C2 in a sagittal direction such that it was angled

posteriorly and exited the posterior tip of the odontoid. The appropriate trajectory was determined, using fluoroscopic guidance, in both the anteroposterior and lateral planes. The optimal drill entry point was the interior endplate of C2. A drill guide system was placed over the K wire once the pilot hole was made. The drill was passed through the body of C2 to the fracture line, and after the surgeon was assured that the spine remains aligned, a hole was drilled to and then through the posterior apex of the odontoid. The drill was removed, the pilot hole was tapped, and a lag screw was inserted through the guide tube through the fracture. It should be emphasized that frequent imaging was useful in achieving optimal trajectory through the fracture. After the screw crossed the fracture line, the threads engaged the fragment and the lag effect of the screw reduced displaced fragments. This lag effect not only closed the fracture gap but also directly opposed the fractured bone edges and provided compression. Immediate stability was confirmed by fluoroscopically observing neck flexion and extension.

The wound was closed in standard fashion. The patients had to wear a collar for 4 to 6 weeks. The patients were usually discharged within 72 hours. Outcome was assessed based on the degree of neck pain and neck motion at serial follow-up visits.

## RESULTS

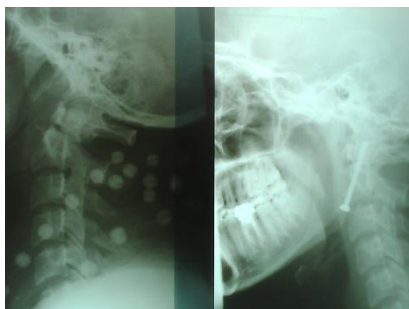There were 26 male and 11 female patients with type II-A odontoid process fracture whose ages ranged from 8 to 67 years (mean 27.27 years). The modes of injury in 35 cases were road traffic accident and the other 2 cases due to falls (Figure 1).



**Figure 1.** Pre and post operation X-ray of an 18 yr-old man with odontoid fracture due to car accident

The 26 cases who were conscious had severe neck pain. Eight cases presented with

incomplete quadriplegia of grade 2/5 motor power and 3 cases with grade 3/5 motor power. In one case, there was complete paraplegia due to T2-T3 fracture and dislocation. In other cases, there was no motor deficit. Eleven patients had associated severe head injury. Brain CT was also performed to exclude associated head injury (Figure 2).



**Figure 2.** Pre and post operation imaging of 28 years old woman with traumatic odontoid fracture

In all 37 cases, the screw could be successfully introduced crossing the fracture site and engaging the dens. All patients were followed in 1, 2, 3, and 6 months. On follow up, all cases (100%) achieved good fusion. There was no case of non-union even after five years. There were no major neurological complications. None of the patients developed operative site infection, CSF fistula, esophageal tear, submandibular fistula or hypoglossal nerve paresis. There was no screw breakage in the follow-up.

Transient dysphagia was present in 18 cases, which improved. Patients with preoperative motor power of grade 2/5 in the limbs with incomplete transverse myelopathy also improved over a span of 6 months and were independently ambulant.

## DISCUSSION

Odontoid fracture is the most common axis injury. The incidence of dens fracture increases with age. As a general concept, the management of odontoid fractures is based on the time of diagnosis, reduction of the fracture, and sufficient immobilization to permit healing. Until the last decade, odontoid fractures were feared because of high morbidity and dramatic radiological and clinical findings. However, they have now become curable, benign traumatic lesions thanks to developments in spinal surgery [15].

Operative stabilization is preferred by most authors over external immobilization for the

treatment of type II fractures of the odontoid process [2, 12, 16]. Although various internal fixation methods using either anterior or posterior approach have been described for the treatment of these fracture types, the optimal surgical method remains controversial [2, 17-21].

To overcome the limitations associated with either conservative or posterior surgical methods for odontoid fracture stabilization, surgeons at many centers have begun to use direct anterior screw fixation to treat Type II and some Type III fractures. Direct anterior screw fixation is an osteosynthetic technique that can provide immediate spinal stabilization. Anterior screw fixation can preserve normal C1-2 rotatory motion [12, 22]. In 83% of patients, full range of motion was maintained after anterior screw fixation of odontoid fractures [23]. Since the reports by Nakan-ishi et al. and Böhler, anterior screw fixation has become the most widely used procedure for stabilization of type II and rostral shallow type III odontoid fractures [18, 24-25]. This method has several advantages over posterior C1-2 fusion, namely, less surgical soft-tissue trauma, no requirement for bone grafting, a lower risk of injury to vertebral arteries, and preservation of C1-2 rotational motion [12, 18, 24].

The technique of single-screw anterior odontoid fixation for the treatment of Type II and rostral Type III odontoid fractures has been previously described by many authorities [12, 14, 26-32] but the main issue concerns the use of single versus multiple screws for fixation of the fractured odontoid process. Early studies favored the use of two screws for fracture reduction [12, 26, 30, 33-34]. The emphasis of those reports centered on the concept of multiple points of fracture fixation. Two points of fixation would theoretically increase the strength of the constructs but would not provide additional resistance to rotational forces. More recent studies, using a single screw, have failed to identify any significant difference in the fusion rates [27, 33, 35-37]. Sasso et al. performed biomechanical testing on cadaveric specimens and failed to demonstrate a significant difference in load-bearing capacities between fractures treated with one or two odontoid screws [36]. Graziano et al. were unable to identify any difference between single- and multiple-screw odontoid fixation, compared with primary C1-C2 posterior wiring techniques, with respect to torsion and bending strengths [9]. McBride et al. demonstrated significantly greater torsional and shear stiffness in odontoid constructs with a single Herbert screw, compared with two AO screws

[11]. Most recently, Jenkins et al. observed no difference in fusion rates for patients receiving one versus two odontoid screws [38].

Because placement of a second screw is associated with additional risk but is not associated with a clear biomechanical advantage, our group advocates odontoid fracture fixation with a single screw. We used one 3.5 mm diameter, cannulated and lag screw construct. The cannulated screw can be inserted over a guide wire and this makes the procedure easy and convenient. The lag screw alloy provides excellent strength and biocompatibility. The leading thread of lag screws penetrate the bone faster than the trailing threads, which reduce the gap and compresses the fractured fragments as the screw is being inserted.

#### Conclusion

In the management of Type II odontoid fractures, single-screw fixation via an anterior approach represents an effective and safe method of treatment. The documented fusion rate of 100% and the few screw-related complication rates in our case series compare favorably with the results from other odontoid screw series and reports of posterior atlantoaxial arthrodesis. Patient selection, meticulous surgical technique, and postoperative immobilization are keys to successful outcomes.

#### ACKNOWLEDGEMENTS

The authors would like to thank Dr. Ali Nazemi Rafi for his expert assistance in the preparation of the manuscript.

#### REFERENCES

- Puttlitz CM, Goel VK, Clark CR, Traynelis VC. Pathomechanisms of failures of the odontoid. *Spine*. 2000;25(22):2868-76.
- Anderson LD, D'Alonzo RT. Fractures of the odontoid process of the axis. *J Bone Joint Surg Am*. 1974;56(8):1663-74.
- Apfelbaum RI, Lonser RR, Veres R, Casey A. Direct anterior screw fixation for recent and remote odontoid fractures. *Journal of Neurosurgery: Spine*. 2000;93(2):227-36.
- Platzer P, Thalhammer G, Ostermann R, Wieland T, Vécsei V, Gaebler C. Anterior screw fixation of odontoid fractures comparing younger and elderly patients. *Spine*. 2007;32(16):1714-20.
- Brooks AL, Jenkins E. Atlanto-axial arthrodesis by the wedge compression method. *J Bone Joint Surg Am*. 1978;60(3):279-84.
- Gallie W. Fractures and dislocations of the cervical spine. *Am J Surg*. 1939;46(3):495-9.
- Sonntag VKH DC, Vardiman A. Anterior odontoid screw fixation. *Principles of Spinal Surgery*. New York: McGraw-Hill; 1996. p. 1039-49.
- Koller H, Kammermeier V, Ulbricht D, Assuncao A, Karolus S, van den Berg B, et al. Anterior retropharyngeal fixation C1-2 for stabilization of atlantoaxial instabilities: study of feasibility, technical description and preliminary results. *Europ Spine J*. 2006;15(9):1326-38.
- Graziano G, Jagers C, Lee M, Lynch W. A comparative study of fixation techniques for type II fractures of the odontoid process. *Spine*. 1993;18(16):2383-7.
- Jeanneret B, Magerl F. Primary posterior fusion C1/2 in odontoid fractures: indications, technique, and results of transarticular screw fixation. *J Spinal Disord*. 1992;5(4):464-75.
- McBride AD, Mukherjee DP, Kruse RN, Albright JA, McBride A. Anterior Screw Fixation of Type II Odontoid Fractures: A Biomechanical Study. *Spine*. 1995;20(17):1855-8.
- Geisler FH, Cheng C, Poka A, Brumback RJ. Anterior screw fixation of posteriorly displaced type II odontoid fractures. *Neurosurgery*. 1989;25(1):30-8.
- Montesano PX, Juach EC, Anderson PA, Benson DR, Hanson PB. Biomechanics of cervical spine internal fixation. *Spine*. 1991;16(3):S10-S6.
- Montesano PX, Anderson PA, Schlehr F, Thalgott JS, Lowrey G. Odontoid fractures treated by anterior odontoid screw fixation. *Spine*. 1991;16(3):S33-S7.
- Nader S, Akfian Ö. Odontoid fractures. *Turk Neurosurg*. 2006;16(2):81-4.
- Fountas KN, Kapsalaki EZ, Karampelas I, Feltes CH, Dimopoulos VG, Machinis TG, et al. Results of long-term follow-up in patients undergoing anterior screw fixation for type II and rostral type III odontoid fractures. *Spine*. 2005;30(6):661-9.
- Koivikko M, Kiuru MJ, Koskinen SK, Myllynen P, Santavirta S, Kivisaari L. Factors associated with nonunion in conservatively-treated type-II fractures of the odontoid process. *Journal of Bone & Joint Surgery, British Volume*. 2004;86(8):1146-51.
- Agrillo A, Russo N, Marotta N, Delfini R. Treatment of remote type II axis fractures in the elderly: feasibility of anterior odontoid screw fixation. *Neurosurgery*. 2008;63(6):1145-51.
- Börm W, Kast E, Richter H-P, Mohr K. Anterior screw fixation in type II odontoid fractures: is there a difference in outcome between age groups? *Neurosurgery*. 2003;52(5):1089-94.
- Dailey AT, Hart D, Finn MA, Schmidt MH, Apfelbaum RI. Anterior fixation of odontoid fractures in an elderly population: clinical article. *Journal of Neurosurgery: Spine*. 2010;12(1):1-8.
- Majercik S, Tashjian RZ, Biffl WL, Harrington DT, Cioffi WG. Halo vest immobilization in the elderly: a death sentence? *J Trauma Acute Care Surg*. 2005;59(2):350-7.
- Sasso RC. C2 dens fractures: treatment options. *J Spinal Disord*. 2001;14(5):455-63.
- Tashjian RZ, Majercik S, Biffl WL, Palumbo MA, Cioffi WG. Halo-vest immobilization increases

- early morbidity and mortality in elderly odontoid fractures. *J Trauma Acute Care Surg.* 2006;60(1):199-203.
24. Tun K, Kaptanoglu E, Cemil B, Yorubulut M, Karahan ST, Tekdemir I. Anatomical study of axis for odontoid screw thickness, length, and angle. *Europ Spine J.* 2009;18(2):271-5.
  25. Andersson S, Rodrigues M, Olerud C. Odontoid fractures: high complication rate associated with anterior screw fixation in the elderly. *Europ Spine J.* 2000;9(1):56-9.
  26. Lee S-H, Sung J-K. Anterior odontoid fixation using a 4.5-mm Herbert screw: the first report of 20 consecutive cases with odontoid fracture. *Surg Neurol.* 2006;66(4):361-6.
  27. Aebi M, ETTER C, COSCIA M. Fractures of the Odontoid Process Treatment with Anterior Screw Fixation. *Spine.* 1989;14(10):1065-70.
  28. Böhler J. Anterior stabilization for acute fractures and non-unions of the dens. *J Bone Joint Surg.* 1982;64(1):18-27.
  29. Chang K-W, Liu Y-W, Cheng P-G, Chang L, Suen K-L, Chung W-L, et al. One Herbert double-threaded compression screw fixation of displaced type II odontoid fractures. *J Spinal Disord.* 1994;7(1):62-9.
  30. Donovan M. Efficacy of rigid fixation of fractures of the odontoid process. Retrospective analysis of fifty-four cases. *Orthop Trans.* 1979;3:309-14.
  31. Dickman CA, Foley KT, Sonntag VK, Smith MM. Cannulated screws for odontoid screw fixation and atlantoaxial transarticular screw fixation: technical note. *J Neurosurg.* 1995;83(6):1095-100.
  32. Etter C, Coscia M, Jaberg H, AEBI M. Direct anterior fixation of dens fractures with a cannulated screw system. *Spine.* 1991;16(3):S25-S32.
  33. Konstantinou D, Levi A, Sonntag V, Dickman C. Odontoid screw fixation. *BNI Q.* 1997;13:14-9.
  34. Laurie SW, Kaban LB, Mulliken JB, Murray JE. Donor-site morbidity after harvesting rib and iliac bone. *Plastic Reconstruc Surg.* 1984;73(6):933-8.
  35. Ryan MD, Taylor TK. Odontoid fractures in the elderly. *J Spinal Disord.* 1993;6(5):397-401.
  36. Sasso R, Doherty BJ, Crawford MJ, Heggeness MH. Biomechanics of Odontoid Fracture Fixation: Comparison of the One-and Two-Screw Technique. *Spine.* 1993;18(14):1950-3.
  37. Reindl R, Sen M, Aebi M. Anterior instrumentation for traumatic C1-C2 instability. *Spine.* 2003;28(17):E329-E33.
  38. Jenkins JD, Coric D, Branch Jr CL. A clinical comparison of one-and two-screw odontoid fixation. *J Neurosurg.* 1998;89(3):366-70.